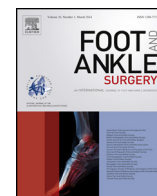



Contents lists available at ScienceDirect

Foot and Ankle Surgery

journal homepage: www.elsevier.com/locate/fas



Syndesmosis fixation in supination-external rotation ankle fractures. Long-Term results of a prospective randomised study

Ristomatti Lehtola^{a,e,*}, Hannu-Ville Leskelä^a, Tapio E. Flinkkilä^a, Harri J. Pakarinen^{a,b}, Jaakko L. Niinimäki^c, Pasi P. Ohtonen^d, Tero H. Kortekangas^a

^a Department of Surgery, Division of Orthopaedic and Trauma Surgery, Oulu University Hospital, Kajaanintie 50, P.O. Box 21, FI 90029 OYS Oulu, Finland

^b Pohjola Sairaala, Kiilakivenkuja 1, 90250 Oulu, Finland

^c Department of Radiology, Oulu University Hospital, Kajaanintie 50, P.O. Box 21, FI 90029 OYS Oulu, Finland

^d Division of Operative Care, Oulu University Hospital, Kajaanintie 50, P.O. Box 21, FI 90029 OYS Oulu, Finland

^e Medical Research Center Oulu, University of Oulu, Pentti Kaiteran Katu 1, P.O. Box 8000, FI-90014 Oulu, Finland

ARTICLE INFO

Article history:

Received 12 October 2020

Received in revised form 11 February 2021

Accepted 19 March 2021

Available online xxx

Keywords:

Supination-external rotation

Weber B

Ankle fracture

Stress test

Syndesmosis

Transfixation

ABSTRACT

Background: The clinical relevance and treatment of syndesmosis injury in supination-external rotation (SER) ankle fractures are controversial.

Methods: After malleolar fixation 24 SER 4 ankle fracture patients with unstable syndesmosis in external rotation stress test were randomised to syndesmosis transfixation with a screw (13 patients) or no fixation (11 patients). Mean follow-up time was 9.7 years (range, 8.9–11.0). The primary outcome measure was the Olerud-Molander Ankle Outcome Score (OMAS). Secondary outcome measures included ankle mortise congruity and degenerative osteoarthritis, 100-mm visual analogue scale for function and pain, RAND 36-Item Health Survey, and range of motion.

Results: Mean OMAS in the syndesmosis transfixation group was 87.3 (SD 15.5) and in the no-syndesmosis-fixation group 89.0 (SD 16.0) (difference between means 1.8, 95% CI –10.4–14.0, $P = 0.76$). There were no differences between the two groups in secondary outcome measures.

Conclusion: With the numbers available, SER 4 ankle fractures with unstable syndesmosis can be treated with malleolar fixation only, with good to excellent long-term functional outcome.

© 2021 Published by Elsevier Ltd on behalf of European Foot and Ankle Society.

1. Introduction

The clinical relevance and treatment of concomitant syndesmosis injury with ankle fractures are controversial [1–10]. Biomechanical evidence suggests that syndesmosis transfixation is not needed in Lauge-Hansen supination-external rotation (SER) ankle fractures [2], which is the most common type of ankle fracture [11–14]. Three clinical series have confirmed these biomechanical findings by Boden et al. [2,4,15,16]. However, several retrospective and prospective case series studies have shown that syndesmosis instability and widening of the distal tibiofibular joint results in poor clinical outcome, pain, and early degenerative osteoarthritis (OA), mainly in high fibular (Lauge-

Hansen pronation-external rotation/Weber C -type) fractures [1,11,16–18]. Therefore, many authors recommend syndesmosis transfixation in ankle fractures presenting with an unstable syndesmosis in the syndesmosis stress test after fracture fixation, even in SER fractures [1,6,16,18–23].

Syndesmosis transfixation with a screw restrains normal motion of the distal tibiofibular joint [24–26]. In addition, syndesmosis malreduction rates when using syndesmosis transfixation vary from 16 to 52%, and malreduction may lead to inferior clinical outcome [4,18,27–30]. The use of syndesmosis transfixation screw might also lead to additional surgery due to removal of the screw, especially if quadricortical transfixation screw is used [24,31–33]. Reported syndesmotic screw removal rates vary from 6 to 100%, depending on hospital protocol and whether a tri- or quadricortical screw is used [34–36]. Due to problems and possible additional surgeries related to syndesmosis transfixation with a screw, unnecessary use of transfixation screw should be avoided.

Only two prospective randomised studies have compared syndesmosis fixation with no fixation in cases of unstable syndesmosis in conjunction with ankle fractures [4,7]. Pakarinen et al. in their randomised controlled trial (RCT) compared

* Corresponding author at: Oulu University Hospital, Kajaanintie 50, P.O. Box 21, FI 90029 OYS Oulu, Finland.

E-mail addresses: ristomatti.lehtola@ppshp.fi (R. Lehtola), hannu-ville.leskela@ppshp.fi (H.-V. Leskelä), tapio.flinkkila@ppshp.fi (T.E. Flinkkilä), harri.pakarinen@fimnet.fi, harripakarinen@fimnet.fi (H.J. Pakarinen), jaakko.niinimaki@ppshp.fi (J.L. Niinimäki), pasi.ohtonen@oulu.fi (P.P. Ohtonen), tero.kortekangas@ppshp.fi (T.H. Kortekangas).

syndesmosis screw fixation with no syndesmosis fixation in SER 4/Weber B-type ankle fractures with unstable syndesmosis after malleolar fixation and found no difference in functional outcome, or pain after one year follow-up [7]. Mid-term results (mean follow-up 4.8 years) of the same RCT showed no differences between the two groups in functional outcome, pain or radiological findings [8]. Kennedy et al. (2000) found similar results in a quasi-randomised study with low Weber C ankle fractures [4].

This study is an extension of a previous RCT [7,8], comparing syndesmosis transfixation with no syndesmosis fixation in patients with SER 4/Weber B-type fractures presenting unstable syndesmosis after malleolar fixation in a standardised (7.5 Nm) external rotation stress test (ER-test). The aim of our study was to present long-term clinical and radiographical follow-up results.

2. Patients and methods

The local ethics review board approved the study plan and all patients gave written informed consent. The study was conducted in accordance with the Declaration of Helsinki. The original study was registered at ClinicalTrials.gov (NCT01234493).

Pakarinen et al., using an intraoperative ER stress test, identified 24 patients with unstable syndesmosis after fixation of malleolar

fractures out of 140 operatively treated patients aged 16 years or older with Lauge-Hansen SER 4/Weber B-type ankle fractures from July 2007 to June 2009 at Oulu University Hospital [7].

The primary hypothesis was that anatomical reduction of malleolar fractures allows the syndesmosis to heal properly and syndesmosis transfixation is not needed.

The power calculations showed that 30 patients per group would be enough to show a clinically significant 20% difference in Olerud-Molander Ankle Outcome Score (OMAS) between the groups (standard deviation [SD] 24 points, $\alpha = 0.05$, $\beta = 0.2$, and 20% estimated drop-out). However, the study was terminated prior to completion due to an unexpectedly low incidence of syndesmosis injuries (24/140 patients, 17%), and interim analysis showed no differences between the groups. Post hoc power analysis of the results showed that 199 patients per group would have been needed to obtain enough statistical power [8].

The lateral malleolus fracture was fixed with two 3.5-mm cortical screws or with a one-third tubular plate with or without a lag screw. Medial malleolar fractures were fixed with two partially-threaded 3.5-mm cancellous screws. If posterior malleolus fracture involved over 30 % of the articular surface on the lateral radiograph, it was fixed with 3.5-mm partially-threaded cancellous screws from anterior to posterior. After malleolar

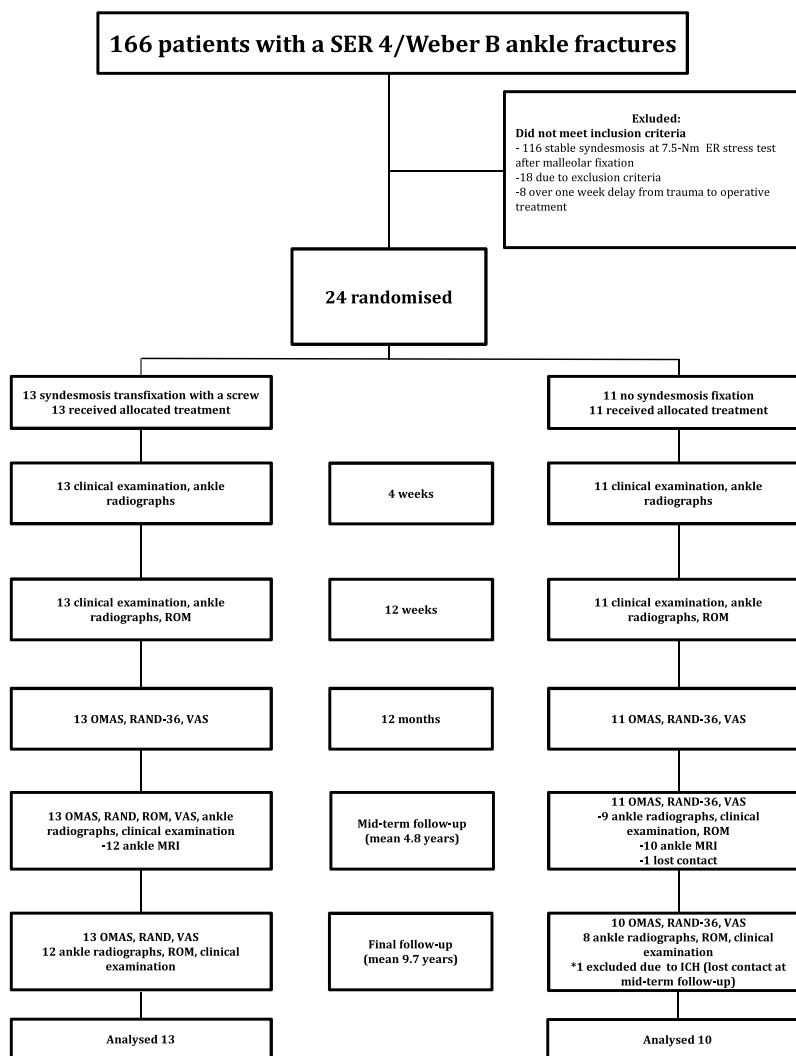


Fig. 1. Study flowchart.

SER, supination external rotation; ER, external rotation; ROM, range of motion; OMAS, Olerud-Molander Ankle Outcome Score; RAND-36, RAND 36-Item Health Survey; VAS, visual analogue scale; MRI, magnetic resonance imaging; ICH, intracranial haemorrhage.

fixation syndesmosis stability was assessed intraoperatively by standardised 7.5-Nm ER-test for both ankles [7,20,37]. ER-test was done using a F-tool-like fork as described by Jenkinson et al. [20]. A positive test result was defined as more than 2-mm side-to-side difference in tibiotalar or tibiofibular clear spaces (TTCS, TFCS). Thirteen patients were randomised to the syndesmosis transfixation group with one 3.5 mm tricortical screw, and 11 to the no-syndesmosis-fixation group.

All patients had a similar postoperative protocol of immobilisation for 4 weeks with a synthetic below-the-knee cast and weight bearing as tolerated [7].

The primary outcome measure was the OMAS [38,39]. Secondary outcome measures included a 100-mm visual analogue scale (VAS) for function and pain [40], the RAND 36-Item Health Survey (RAND-36, for health-related quality of life) [41], range of motion (ROM) of the injured ankle [42,43], and radiographic findings (Talocrural joint [TC] OA and ankle mortise congruity) [44]. Individual RAND-36 results were also compared with results of an age-matched pair from the general population. Questionnaires along with the consent forms were sent to the patients via postal mail and completed questionnaires and consent forms were collected at the outpatient clinic visit. If the patient was unable to attend the follow-up visit the completed questionnaires and consent forms were returned via postal mail.

Mean follow-up time was 9.7 years (range, 8.9–11.0). Twenty-three patients (13 transfixation, 10 no fixation) returned completed consent forms and questionnaires. Outpatient visits were carried out from December 2017 to January 2019.

Twenty patients (12 transfixation, 8 no-fixation group) attended the outpatient clinic visit. At the outpatient clinic the patients were interviewed, the injured ankle was examined, and ROM was measured. Standing mortise and lateral plain radiographs were taken. Any additional past operations of the injured ankle were recorded. An orthopedic resident who had completed university hospital trauma training or a senior orthopedic trauma surgeon conducted the clinical examination. Doctors carrying out the follow-up visits were blinded to group allocation when possible. ROM of the injured ankle was measured using a goniometer [42,43].

One patient from the no-syndesmosis-fixation group was excluded due to intracranial haemorrhage (approximately 10 years after the index trauma) and loss of ambulatory function.

A study flowchart is shown in Fig. 1.

2.1. Radiological assessment

TC joint congruity was assessed from the plain standing ankle radiographs by TTCS and TFCS. Measurements were done on a diagnostic workstation to 1-mm accuracy. The measurements were calibrated using a 30-mm calibration disc and the dimensions of a small fragment fixation screw (3.5-mm; Synthes, Valencia, CA).

Radiological assessment and grading of OA were done from plain radiographs by an experienced musculoskeletal radiologist who was blinded to the clinical outcome. TC joint OA was graded according to the Kellgren-Lawrence classification (K–L) [44].

2.2. Randomisation

A computer-generated randomisation list was generated by a biostatistician independent of the treatment process. The randomisation process was done in 1:1 ratio with randomly changing block sizes of 4 and 6. Sequentially numbered and sealed envelopes to allocate each patient to syndesmosis transfixation or the no-syndesmosis-fixation group were done by a research assistant who was not involved in patient clinical care. If the ER-test was positive,

the operating surgeon performed the randomisation by opening the next available sealed envelope.

2.3. Statistical analysis

All analyses were performed using IBM SPSS Statistics for Windows, Version 25.0. Armonk, NY: IBM Corp.) and SAS (version 9.4, SAS Institute, Cary, NC). Summary measurements are presented as mean with standard deviation (SD) unless other stated. Student's *t*-test or the Welch test was used to compare continuous variables, the latter if variances were heterogeneous. Pearson's χ^2 -test or Fisher's exact test were used for categorical variables. For repeatedly measured continuous variables, we used a repeated-measures mixed-model ANOVA with time, group, and time \times group as fixed effects and patient as a random effect. As the repeated-measures mixed model allows the analysis of unbalanced datasets without imputation, we analysed all available data. We report the between-group differences for all continuous outcomes, and 95% confidence intervals (CI) according to the repeated-measures mixed model. Two-tailed *P* values are reported. *P* value <0.05 was considered statistically significant.

3. Results

Baseline data for study groups is presented in Table 1.

At the final follow-up, mean OMAS in the syndesmosis transfixation group was 87.3 (SD 15.5) and in the no-syndesmosis-fixation group 89.0 (SD 16.0) (difference between means 1.8, 95% CI: –10.4–14.0, *P* = 0.767). VAS (pain and function), RAND 36-item health survey (physical and bodily pain), and ROM did not differ significantly between the two groups at final follow-up (Table 2).

No differences were detected between the study population and general population in terms of RAND-36 (physical and bodily pain) (mean difference 5.8, 95% CI: –0.3–11.8, *P* = 0.062; and 3.6, 95% CI: –7.1–14.2, *P* = 0.496, respectively, both in favor of the study population).

In weight-bearing radiographs, the ankle mortise remained congruent in all patients (Table 3). In the syndesmosis transfixation group all patients had K–L 2 OA in the TC joint. In the no-syndesmosis-fixation group 1 patient had K–L 1, 5 patients K–L 2, and two patients K–L 3 OA. Only in 1 patient (in the syndesmosis transfixation group) did the OA grade deteriorate from K–L 1 to K–L 2 between the mid-term and final follow-up visit.

In 2 patients the syndesmosis screw was broken and left in place, and 4 patients had had the screw removed due to local

Table 1
Patient characteristics at baseline.

	Syndesmosis transfixation	No syndesmosis fixation
N	13	11
Age (mean, years)	42.5 (SD 11.6)	44.9 (SD 14.2)
Gender (male/female)	8/5	7/4
SER4/Weber B ankle fracture	13/13	11/11
Fracture characteristics		
Fibula only	9	6
Fibula + medial malleolus	1	2
Fibula + posterior malleolus	1	3
Trimalleolar	2	0
Open fracture	0	0
Comorbidities	4	1

N, number of patients; SD, standard deviation; SER4, Lauge-Hansen supination-external rotation type 4 ankle fracture. Comorbidities: diabetes, arteriosclerosis obliterans, alcoholism.

Table 2
Functional parameters during the follow-up and between-group differences at final follow-up.

	1 year	Mid-term	Final follow-up	Difference between means ^a	95% Confidence interval ^a	P ^a
Olerud-Molander, mean (SD)						
Syndesmosis transfixation	79.6 (15.5)	81.2 (16.3)	87.3 (15.5)	1.8	–10.4–14.0	0.767
No syndesmosis fixation	83.6 (13.1)	92.7 (9.3)	89.0 (16.0)			
VAS function ^b , mm, mean (SD)						
Syndesmosis transfixation	22.6 (24.6)	11.6 (15.2)	16.2 (21.8)	–2.2	–17.3–12.9	0.765
No syndesmosis fixation	14.8 (15.0)	5.6 (7.9)	14.6 (20.7)			
VAS pain ^b , mm, mean (SD)						
Syndesmosis transfixation	25.5 (25.4)	10.7 (14.9)	10.5 (13.1)	1.5	–13.2–16.2	0.836
No syndesmosis fixation	11.3 (12.5)	4.3 (8.0)	12.2 (22.1)			
RAND-36 physical, mean (SD)						
Syndesmosis transfixation	78.3 (23.3)	85.8 (19.0)	84.6 (19.7)	5.5	–10.1–21.1	0.478
No syndesmosis fixation	88.3 (18.7)	92.3 (14.6)	89.5 (20.1)			
RAND-36 pain, mean (SD)						
Syndesmosis transfixation	63.4 (33.0)	78.4 (22.5)	69.8 (25.2)	16.2	–2.3–34.7	0.085
No syndesmosis fixation	84.4 (13.7)	89.1 (12.8)	85.0 (20.2)			
Range of motion, degree, mean (SD)						
Syndesmosis transfixation	62.9 (11.6) ^c	75.8 (9.8)	68.4 (19.0)	3.8	–7.7–15.2	0.512
No syndesmosis fixation	58.5 (11.8) ^c	75.0 (10.8)	71.6 (7.0)			

^a at final follow-up.^b Range 0–100, with higher scores indicating more severe pain or dysfunction.^c Measurement at 12 weeks.**Table 3**
Radiographic measurements during follow-up and between-group differences at final follow-up.

	12 weeks	Mid-term	Final follow-up	Difference between means ^a	95% Confidence interval ^a	P ^a
TTCS, mean (SD)						
Syndesmosis transfixation	3.5 (0.8)	2.8 (0.8)	2.8 (0.8)	0.6	–0.1–1.2	0.077
No syndesmosis fixation	3.2 (0.6)	2.9 (0.8)	3.3 (0.7)			
TFCs, mean, (SD)						
Syndesmosis transfixation	5.4 (2.0)	5.5 (1.3)	5.0 (1.7)	0.9	–0.4–2.2	0.174
No syndesmosis fixation	5.5 (1.2)	5.9 (0.9)	6.1 (1.1)			

TTCS, tibiotalar clear space; TFCs, tibiofibular clear space.

^a At final follow-up.

irritation. Six patients had an intact transfixation screw in place, and all showed signs of loosening in the radiographs.

4. Discussion

In this long-term follow-up of a prospective randomised study, we found that in patients with SER 4/Weber B –type ankle fractures and unstable syndesmosis after fracture fixation, syndesmosis transfixation compared with no syndesmosis fixation yielded similar functional and radiological results after a mean of 9.7 years of follow-up. These long-term results confirm the short- and mid-term results reported previously from this same study [7,8].

According to previous literature, syndesmosis instability is linked to early degenerative changes of the tibiotalar joint and poor functional outcome [1,16,18]. However, the strength of evidence for stabilising nondisplaced unstable syndesmosis in ankle fractures is limited [10]. Also, it is not clear if syndesmosis transfixation in these injuries would improve clinical outcome [10]. According to our study findings, in SER 4/Weber B –type ankle fractures syndesmosis injury will heal properly after anatomical reduction and fixation of malleoli without additional syndesmosis transfixation. The ankle mortise was stable enough after malleoli

fixation to bear weight as tolerated with a synthetic cast, even with an external-rotation-unstable ankle mortise.

After a mean of 9.7 years of follow-up, the study's primary outcome, OMAS, showed similar ankle functional outcome in both groups—mostly from good to excellent. Also, in a previous study these same 24 patients were matched (sex, age and fracture anatomy) with 24 patients with SER 4/Weber B ankle fracture and ER-test stable syndesmosis after malleolar fixation, without any significant differences in terms of functional outcome, pain, or radiographic results [9]. These results are comparable to previously reported long-term follow-up results of SER ankle fractures despite the fact that in the previous study patients with more benign fracture types, from SER 2 to SER 4, were also included [45]. Our results are consistent with the published biomechanical data and clinical studies stating that syndesmosis transfixation is not needed in patients with SER-type ankle fractures [2,4,7,8,15,16].

The secondary outcomes of the study were designed to capture the ankle functional outcome more comprehensively and also the patients' health-related quality of life. These secondary results strengthened the findings of the study's primary outcome by demonstrating that there were no differences between the study groups. Four patients (30%) of the syndesmosis transfixation group

needed additional surgery due to removal of symptomatic transfixation screw, which can be considered as a treatment related harm. Our study syndesmosis screw removal rate is comparable to previously reported removal rates for symptomatic tricortical syndesmosis screws varying from 6 to 60 % [34,36,46].

Analysis from plain standing ankle radiographs revealed no significant differences between groups. From the mid-term to final follow-up, only 1 patient (syndesmosis transfixation group) had OA grade deterioration from K–L 1 to K–L 2. Contrary to earlier thoughts about syndesmosis injury in conjunction with SER/Weber B–type ankle fractures, malleolar fixation only, without syndesmosis transfixation, did not lead to widening of the ankle mortise or early degenerative osteoarthritis [1,47]. Posttraumatic OA usually occurs in the first 2 years after the injury [12], but more severe posttraumatic OA is suggested to develop rapidly [48]. The highest risk for ankle fusion or arthroplasty due to posttraumatic OA after ankle fracture is during the first 3 years after the injury [48], though the development of post-traumatic osteoarthritis has been suggested to take even more time [49,50].

To our knowledge this is the first study reporting long-term follow up results comparing syndesmosis transfixation with no fixation in patients with SER4/Weber B –type ankle fracture and unstable syndesmosis after malleolar fixation. Syndesmosis instability was detected using a reliable and standardised method. Additionally, the long-term follow-up and excellent follow-up rate (96%) strengthen the study's findings. Some limitations warrant discussion, as the small number of patients leaves us with the possibility of a type II error. However, the main reason for the limited number of patients in this study is the chosen two-millimeter side-to-side difference threshold for unstable syndesmosis instead of the one-millimeter threshold used by previous authors [20]. This two-millimeter threshold was chosen to detect significant syndesmosis instability more accurately during the surgery. Additionally, previous follow-up studies of this trial using a variety of different measuring tools have consistently shown almost identical findings across the study groups [7,8]. Not a single case of widened ankle mortise or premature ankle joint osteoarthritis has been found. All this despite the fact that clearly unstable syndesmoses were left unfixed and patients were allowed to bear full weight with a synthetic cast immediately after surgery. According to our results it would be safe to conduct a multicentre study in a larger patient population, to definitively address the indications for syndesmosis transfixation.

5. Conclusion

With the numbers available, it seems that SER 4/Weber B –type ankle fractures with unstable syndesmosis can be treated with malleolar fixation only and have good to excellent ankle functional outcome without an increased risk of widening of the ankle mortise or posttraumatic OA. Due to low number of patients, a multicentre study in a larger patient population is needed, to definitively address the indications for syndesmosis transfixation.

Funding

This research did not receive any specific grant from funding agencies in the public, commercial, or not-for-profit sectors.

Conflict of interest

Authors declare that they have no financial or personal relationships that could influence this study.

References

- [1] Leeds HC, Ehrlich MG. Instability of the distal tibiofibular syndesmosis after bimalleolar and trimalleolar ankle fractures. *J Bone Joint Surg Am* 1984;66(April (4)):490–503.
- [2] Boden SD, Labropoulos PA, McCowin P, Lestini WF, Hurwitz SR. Mechanical considerations for the syndesmosis screw. A cadaver study. *J Bone Joint Surg Am* 1989;71(December (10)):1548–55.
- [3] Clarke HJ, Michelson JD, Cox QG, Jinnah RH. Tibio-talar stability in bimalleolar ankle fractures: a dynamic in vitro contact area study. *Foot Ankle* 1991;11(February (4)):222–7.
- [4] Kennedy JG, Soffe KE, Dalla Vedova P, Stephens MM, O'Brien T, Walsh MG, et al. Evaluation of the syndesmosis screw in low Weber C ankle fractures. *J Orthop Trauma* 2000;14(5):359–66.
- [5] Miller SD. Controversies in ankle fracture treatment. Indications for fixation of stable Weber type B fractures and indications for syndesmosis stabilization. *Foot Ankle Clin* 2000;5(4):841–51.
- [6] Ebraheim NA, Elgafy H, Padanilam T. Syndesmosis disruption in low fibular fractures associated with deltoid ligament injury. *Clin Orthop Relat Res* 2003; (409):260–7.
- [7] Pakarinen HJ, Flinkkilä TE, Ohtonen PP, Hyvonen PH, Lakovaara MT, Leppilähti JI, et al. Syndesmosis fixation in supination-external rotation ankle fractures: a prospective randomized study. *Foot Ankle Int* 2011;32(December (12)):1103–9.
- [8] Kortekangas TH, Pakarinen HJ, Savola O, Niinimäki J, Lepojarvi S, Ohtonen P, et al. Syndesmosis fixation in supination-external rotation ankle fractures: a prospective randomized study. *Foot Ankle Int* 2014;35(October (10)):988–95.
- [9] Kortekangas T, Flinkkilä T, Niinimäki J, Lepojarvi S, Ohtonen P, Savola O, et al. Effect of syndesmosis injury in SER IV (Weber B)-type ankle fractures on function and incidence of osteoarthritis. *Foot Ankle Int* 2015;36(February (2)):180–7.
- [10] Michelson JD, Wright M, Blankstein M. Syndesmosis ankle fractures. *J Orthop Trauma* 2018;32(January (1)):10–4.
- [11] Lauge-Hansen N. Fractures of the ankle. II. Combined experimental-surgical and experimental-roentgenologic investigations. *Arch Surg* 1950;60(May (5)):957–85.
- [12] Michelson JD. Fractures about the ankle. *J Bone Joint Surg Am* 1995;77(January (1)):142–52.
- [13] Jensen SL, Andresen BK, Mencke S, Nielsen PT. Epidemiology of ankle fractures. A prospective population-based study of 212 cases in Aalborg, Denmark. *Acta Orthop Scand* 1998;69(February (1)):48–50.
- [14] Pakarinen HJ, Flinkkilä TE, Ohtonen PP, Ristiniemi JY. Stability criteria for nonoperative ankle fracture management. *Foot Ankle Int* 2011;32(February (2)):141–7.
- [15] Yamaguchi K, Martin CH, Boden SD, Labropoulos PA. Operative treatment of syndesmosis disruptions without use of a syndesmosis screw: a prospective clinical study. *Foot Ankle Int* 1994;15(August (8)):407–14.
- [16] Chissell HR, Jones J. The influence of a diastasis screw on the outcome of Weber type-C ankle fractures. *J Bone Joint Surg Br* 1995;77(May (3)):435–8.
- [17] Weber BG. Die Verletzungen des oberen Sprunggelenkes. Aktuelle Probleme in der Chirurgie. Vienna: Verlag Hans Huber; 1972. p. 51–65.
- [18] Weening B, Bhandari M. Predictors of functional outcome following trans-syndesmosis screw fixation of ankle fractures. *J Orthop Trauma* 2005;19(February (2)):102–8.
- [19] Nielson JH, Sallis JG, Potter HG, Helfet DL, Lorch DG. Correlation of interosseous membrane tears to the level of the fibular fracture. *J Orthop Trauma* 2004;18(February (2)):68–74.
- [20] Jenkinson RJ, Sanders DW, Macleod MD, Domonkos A, Lydestadt J. Intraoperative diagnosis of syndesmosis injuries in external rotation ankle fractures. *J Orthop Trauma* 2005;19(October (9)):604–9.
- [21] Egol KA, Tejwani NC, Walsh MG, Capla EL, Koval KJ. Predictors of short-term functional outcome following ankle fracture surgery. *J Bone Joint Surg Am* 2006;88(May (5)):974–9.
- [22] Stark E, Tornetta 3rd P, Creevy WR. Syndesmosis instability in Weber B ankle fractures: a clinical evaluation. *J Orthop Trauma* 2007;21(October (9)):643–6.
- [23] Tornetta 3rd P, Axelrad TW, Sibai TA, Creevy WR. Treatment of the stress positive ligamentous SE4 ankle fracture: incidence of syndesmosis injury and clinical decision making. *J Orthop Trauma* 2012;26(November (11)):659–61.
- [24] Needleman RL, Skrade DA, Stiehl JB. Effect of the syndesmosis screw on ankle motion. *Foot Ankle* 1989;10(August (1)):17–24.
- [25] Pereira DS, Koval KJ, Resnick RB, Sheskiar SC, Kummer F, Zuckerman JD. Tibiotalar contact area and pressure distribution: the effect of mortise widening and syndesmosis fixation. *Foot Ankle Int* 1996;17(May (5)):269–74.
- [26] Miller RS, Weinhold PS, Dahners LE. Comparison of tricortical screw fixation versus a modified suture construct for fixation of ankle syndesmosis injury: a biomechanical study. *J Orthop Trauma* 1999;13(January (1)):39–42.
- [27] Gardner MJ, Demetrakopoulos D, Briggs SM, Helfet DL, Lorch DG. Malreduction of the tibiofibular syndesmosis in ankle fractures. *Foot Ankle Int* 2006;27(October (10)):788–92.
- [28] Miller AN, Carroll EA, Parker RJ, Boraiah S, Helfet DL, Lorch DG. Direct visualization for syndesmosis stabilization of ankle fractures. *Foot Ankle Int* 2009;30(May (5)):419–26.
- [29] Naqvi GA, Cunningham P, Lynch B, Galvin R, Awan N. Fixation of ankle syndesmosis injuries: comparison of tightrope fixation and syndesmosis screw fixation for accuracy of syndesmosis reduction. *Am J Sports Med* 2012;40(12):2828–35.

- [30] Sagi HC, Shah AR, Sanders RW. The functional consequence of syndesmotric joint malreduction at a minimum 2-year follow-up. *J Orthop Trauma* 2012;26(7):439–43.
- [31] Bell DP, Wong MK. Syndesmotric screw fixation in Weber C ankle injuries—should the screw be removed before weight bearing? *Injury* 2006;37(September (9)):891–8.
- [32] van den Bekerom MP, Hogervorst M, Bolhuis HW, van Dijk CN. Operative aspects of the syndesmotric screw: review of current concepts. *Injury* 2008;39(April (4)):491–8.
- [33] Tucker A, Street J, Kealey D, McDonald S, Stevenson M. Functional outcomes following syndesmotric fixation: a comparison of screws retained in situ versus routine removal - is it really necessary? *Injury* 2013;44(December (12)):1880–4.
- [34] Høiness P, Strømsøe K. Tricortical versus quadricortical syndesmosis fixation in ankle fractures: a prospective, randomized study comparing two methods of syndesmosis fixation. *J Orthop Trauma* 2004;18(6):331–7.
- [35] Schepers T. Acute distal tibiofibular syndesmosis injury: a systematic review of suture-button versus syndesmotric screw repair. *Int Orthop* 2012;36(6):1199–206.
- [36] Boyle MJ, Gao R, Frampton C, Coleman B. Removal of the syndesmotric screw after the surgical treatment of a fracture of the ankle in adult patients does not affect one-year outcomes: a randomised controlled trial. *Bone Joint J* 2014;96(12):1699–705.
- [37] Pakarinen H, Flinkkilä T, Ohtonen P, Hyvonen P, Lakovaara M, Leppilahti J, et al. Intraoperative assessment of the stability of the distal tibiofibular joint in supination-external rotation injuries of the ankle: sensitivity, specificity, and reliability of two clinical tests. *J Bone Joint Surg Am* 2011;93(November (22)):2057–61.
- [38] Olerud C, Molander H. A scoring scale for symptom evaluation after ankle fracture. *Arch Orthop Trauma Surg* 1984;103(3):190–4.
- [39] Nilsson GM, Eneroth M, Ekdahl CS. The Swedish version of OMAS is a reliable and valid outcome measure for patients with ankle fractures. *BMC Musculoskelet Disord* 2013;14(March):109.
- [40] Ponzer S, Nasell H, Bergman B, Tornkvist H. Functional outcome and quality of life in patients with Type B ankle fractures: a two-year follow-up study. *J Orthop Trauma* 1999;13(5):363–8.
- [41] Aalto A, Aro A, Teperi J. RAND 36 terveyteen liittyvän elämänlaadun mittarina (RAND 36 as a measure of quality of life. [In Finnish]). Saarijärvi: Gummerus Kirjapaino Oy; 1999.
- [42] Lindsjo U, Danckwardt-Lilliestrom G, Sahlstedt B. Measurement of the motion range in the loaded ankle. *Clin Orthop Relat Res* 1985;(October (199)):68–71.
- [43] Norkin CC WD. Measurement of Joint Motion: A Guide to Goniometry. 3rd ed. Philadelphia, PA: FA Davis Company; 2003.
- [44] Kellgren JH, Lawrence JS. Radiological assessment of osteo-arthrosis. *Ann Rheum Dis* 1957;16(December (4)):494–502.
- [45] Donken CC, Verhofstad MH, Edwards MJ, van Laarhoven CJ. Twenty-one-year follow-up of supination-external rotation type II-IV (OTA type B) ankle fractures: a retrospective cohort study. *J Orthop Trauma* 2012;26(August (8)):108–14.
- [46] Wikerøy AK, Høiness PR, Andreassen GS, Hellund JC, Madsen JE. No difference in functional and radiographic results 8.4 years after quadricortical compared with tricortical syndesmosis fixation in ankle fractures. *J Orthop Trauma* 2010;24(1):17–23.
- [47] Ebraheim NA, Mekhail AO, Gargasz SS. Ankle fractures involving the fibula proximal to the distal tibiofibular syndesmosis. *Foot Ankle Int* 1997;18(August (8)):513–21.
- [48] Axelrod D, Veljkovic A, Zochowski T, Marks P, Mahomed N, Wasserstein D. Risk of ankle fusion or arthroplasty after operatively and nonoperatively treated ankle fractures: a matched cohort population study. *J Orthop Trauma* 2020;34(January (1)):e1–5.
- [49] Stufkens SA, Knupp M, Horisberger M, Lampert C, Hintermann B. Cartilage lesions and the development of osteoarthritis after internal fixation of ankle fractures: a prospective study. *J Bone Joint Surg Am* 2010;92(February (2)):279–86.
- [50] Lubbeke A, Salvo D, Stern R, Hoffmeyer P, Holzer N, Assal M. Risk factors for post-traumatic osteoarthritis of the ankle: an eighteen year follow-up study. *Int Orthop* 2012;36(July (7)):1403–10.