

Current treatment concepts in skin cancer

Glenn D. Goldman, MD

University of Vermont Medical Center

University of Vermont College of Medicine

Goals

- ◉ Recognize and identify the main types of skin cancer and their precursors
- ◉ Identify and understand new technological improvements in the treatment of skin cancer
- ◉ Develop a rational approach to diagnosis and management

Skin Cancer

- ◉ Increasing incidence w/ more than 1Mil cases per/yr in US
- ◉ **Basal Cell Carcinoma** 85%-90%
- ◉ **Squamous Cell Carcinoma** 10%-15%
- ◉ At least 30% of white men in southern USA get skin cancer at some point in their lives
- ◉ **Melanoma** 1/45 lifetime, Rapid increase

Sun Damage

- ◉ Photoaging: Wrinkling, mottled pigment and onset of actinic keratoses and skin cancer
- ◉ UVB (290-320 nm)
 - > Acute sunburn, mutations
- ◉ UVA (320-400 nm)
 - > Photoaging, promotion

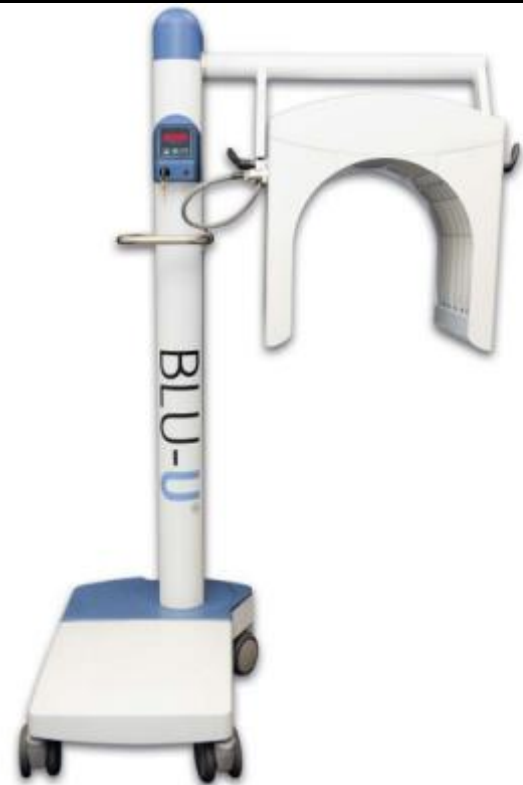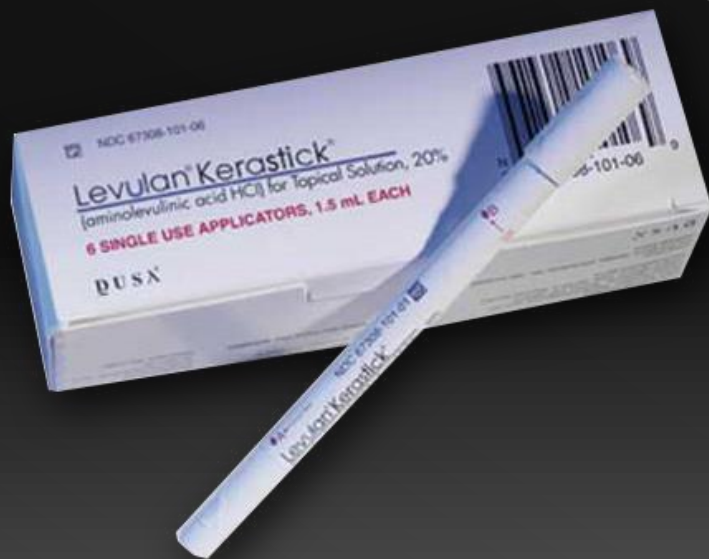Actinic Keratosis (AK)

- ◉ Premalignant sun induced gritty erythematous macules and keratotic papules - No invasion of dermis
- ◉ May progress to squamous carcinoma
- ◉ Often require destruction with liquid nitrogen or 5-fluorouracil
- ◉ A marker for the potential development of cutaneous malignancy
- ◉ Commonly harbor mutations in p53

Treatment of actinic keratoses

- ◉ Liquid nitrogen cryosurgery
- ◉ Curettage and electrodesiccation
- ◉ 5-fluorouracil
- ◉ Imiquimod
- ◉ Ingenol mebutate
- ◉ Photodynamic therapy

Photodynamic therapy



BLU-U® Blue Light Photodynamic Therapy
Illuminator Model 4170

Basal Cell Carcinoma

◎ **Majority of Skin Cancer**

- › Arises from follicular (basal) germ
- › Well over one million cases annually US

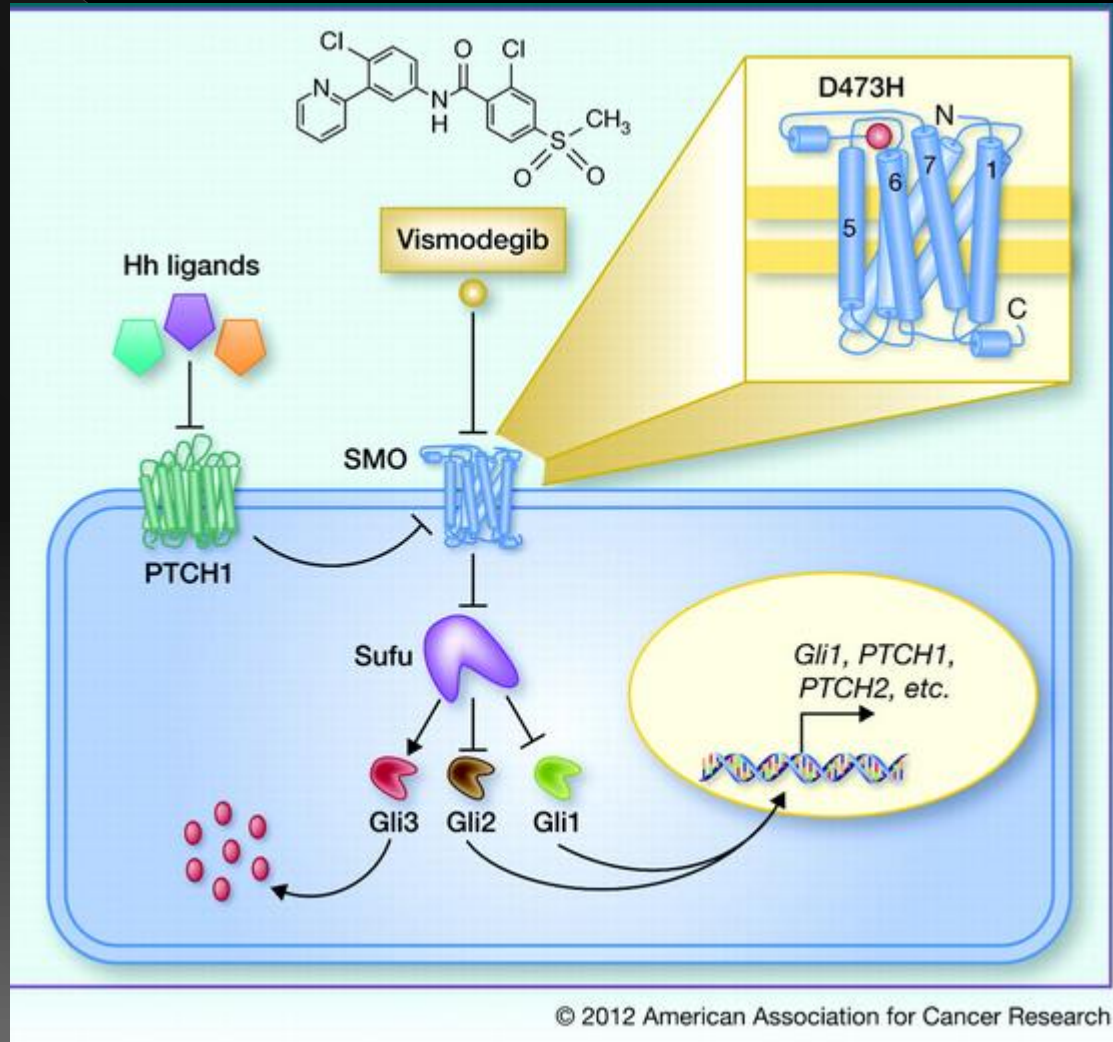
◎ **Indolent but Destructive**

- › Doubling time 1 year
- › Rarely metastasizes
- › Locally highly destructive

New treatments

- ◉ HEDGEHOG gene pathway
- ◉ Vismodegib
- ◉ Oral medication
- ◉ Dramatic shrinkage of tumors
- ◉ Multiple side effects

PTCH / SMO pathway



Squamous Cell Carcinoma

- ◎ **250,00 Cases in USA Annually**

- > Arises from squamous epithelium

- ◎ **Most cutaneous SCC are indolent**

- ◎ **Rapid Growth Potential**

- ◎ **Metastasis**

- > **High risk sites: Ear, Lower Lip**

- > **High risk lesions: > 2 cm diam.**

- ◎ Main risk factor: Sun exposure

Treatment: Basal Cell and Squamous Cell Carcinoma

- ◉ Imiquimod
- ◉ Curettage and Electrodesiccation
- ◉ Tangential excision (shave)
- ◉ Standard excision
- ◉ Excision with frozen sections
- ◉ Mohs microscopically-controlled excision
- ◉ Radiation therapy

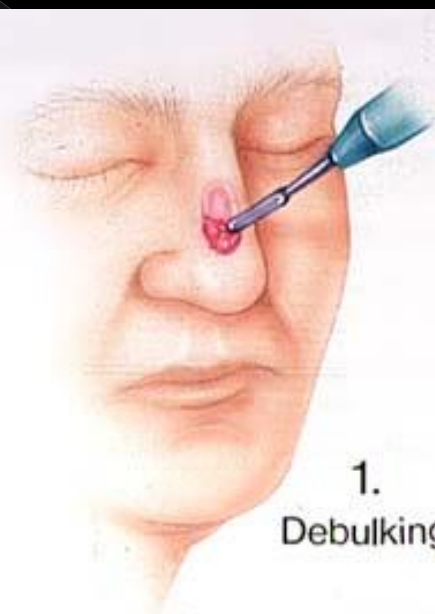
Mohs Micrographic Surgery

- En face frozen sections:

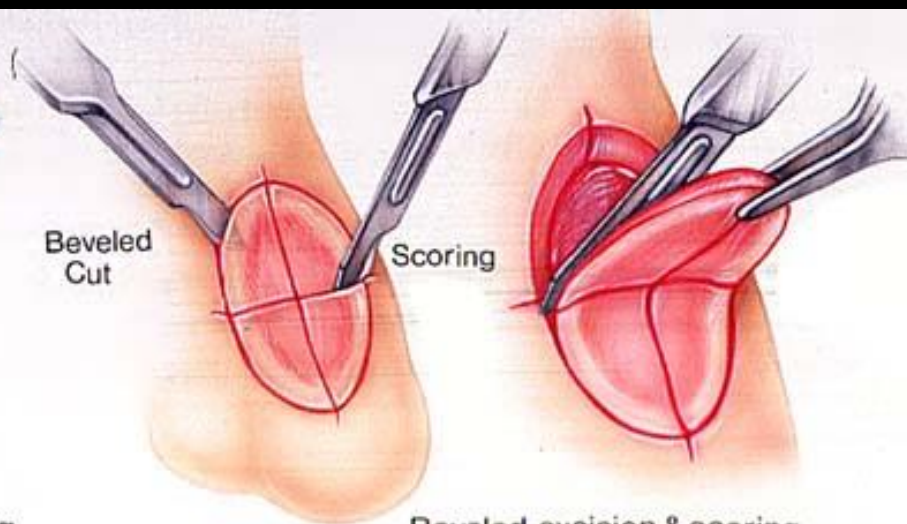
- › Tissue prepared to show **all margins**

- Surgeon is pathologist

- › Almost uniformly **w/local anesthesia**



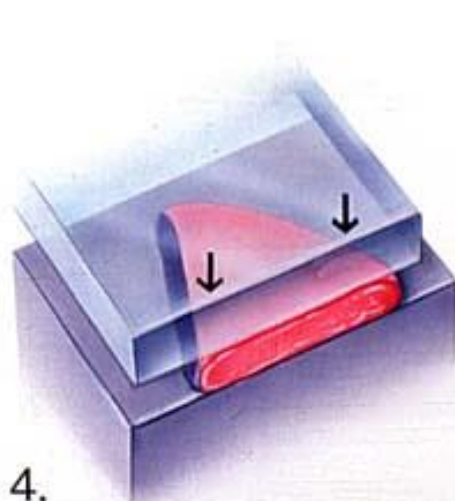
1.
Debulking



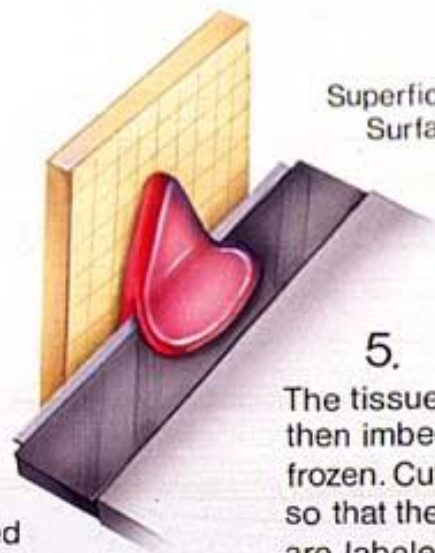
2.
Beveled excision & scoring
on patient for determining
cancer location



3.
Numbering & coding of specimen



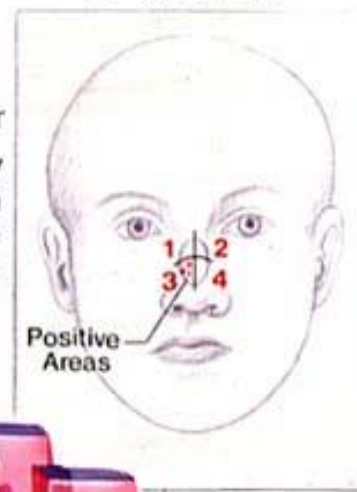
4.
Specimen is inverted & underscored
and edges fall into the same plane



5.
The tissue is
then imbedded &
frozen. Cuts are taken
so that the bottom & edges
are labeled at first

Superficial
Surface

6.
Positive tumor
can be accurately
located & its position
margin in the
surgical map



Positive
Areas

Deep
Surface

Lateral Margin

Advantages of Mohs surgery

- ◉ All margins evaluated
- ◉ Highest cure rate
- ◉ Tissue Sparing
- ◉ Surgeon as pathologist
 - Surgeon has *precise knowledge* of tumor location

Mohs surgery: Indications

Literature:

- ◉ Recurrent BCC or SCC, some MIS
- ◉ Morpheaform or micronodular basal cell carcinoma (Aggressive growth)
- ◉ Lesions in the “T” zone of the face
- ◉ Lesions greater than 2 cm in diameter
- ◉ Facial lesions requiring tissue sparing

In practice:

Facial skin cancer

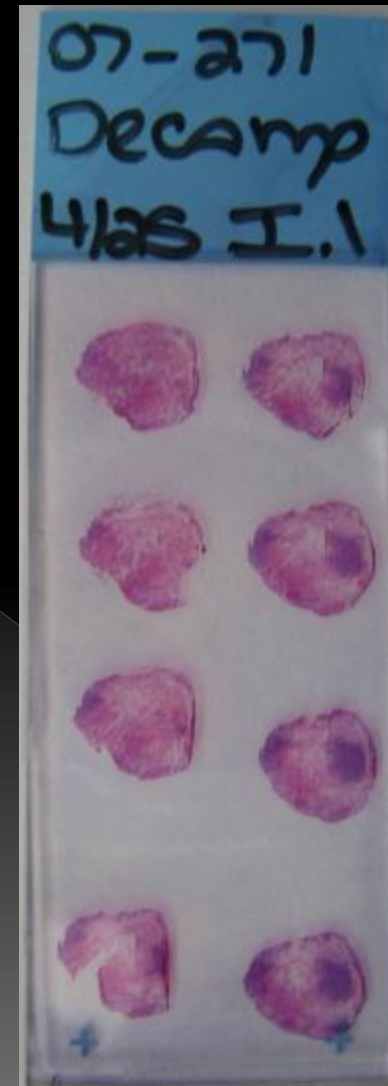
Typical sections

- ◉ The pink is dermis
- ◉ The clear reticular area is subcutaneous fat
- ◉ A small rim of epidermis lines the dermis



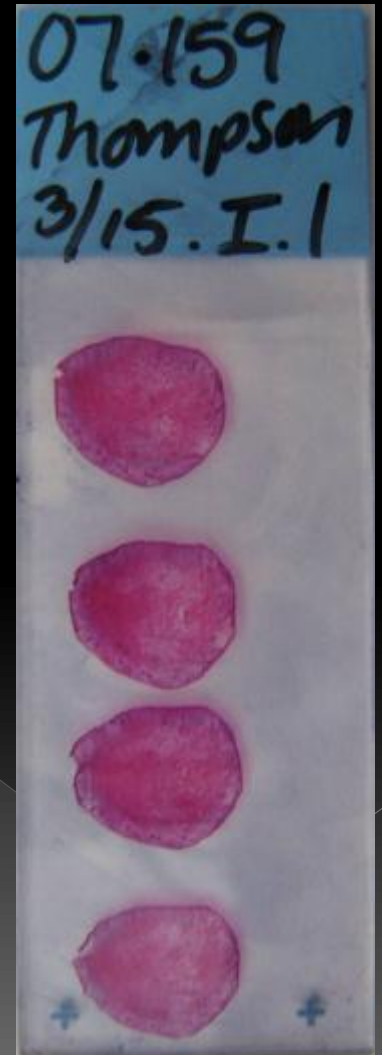
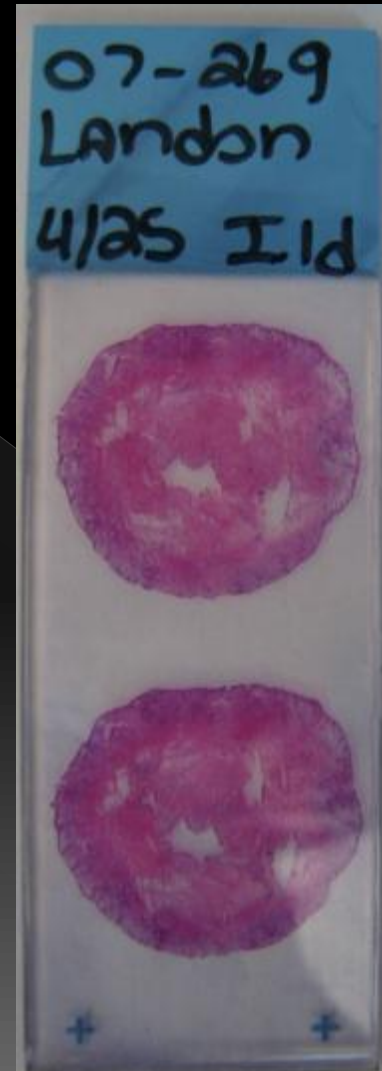
Single section

- ◉ Most accurate first cut/section
- ◉ Easy to follow tumor appearance at depth
- ◉ As you cut into the tissue the tumor (BCC) appears



Single sections

- ◉ Avoids false positive and false negative depth
- ◉ Generally faster
- ◉ Elegant
- ◉ Less slides
- ◉ Easy to match to defect



Mohs Surgery

- ◉ Usually local anesthesia
- ◉ No hospital stay
- ◉ Extensive surgery without hospitalization
- ◉ Moderately expensive
- ◉ Very low complication rate

Nonmelanoma Skin Cancer

Take-home message

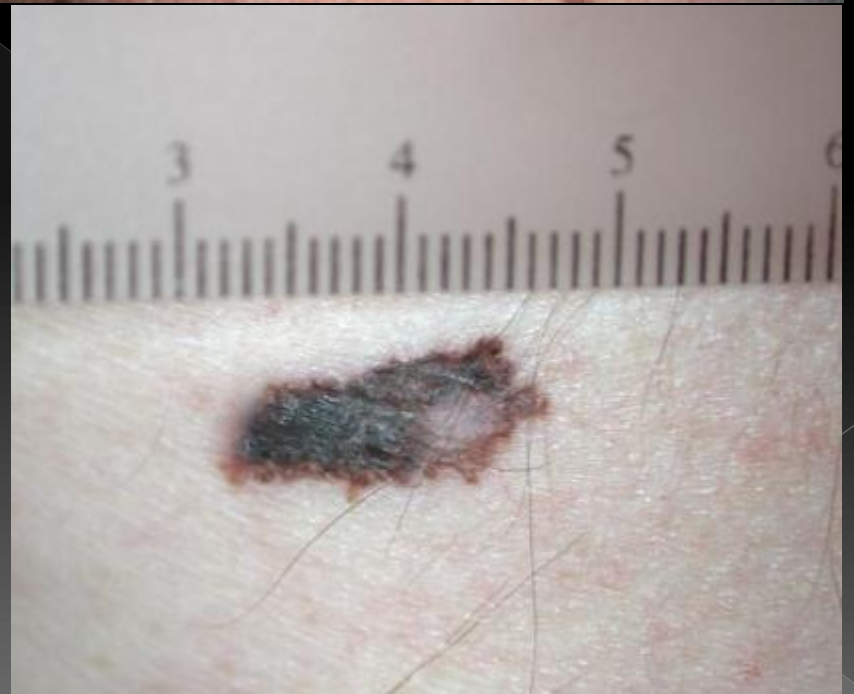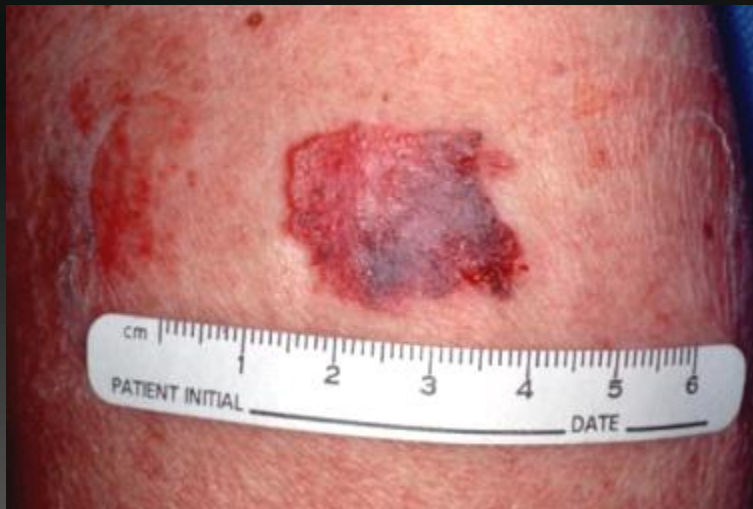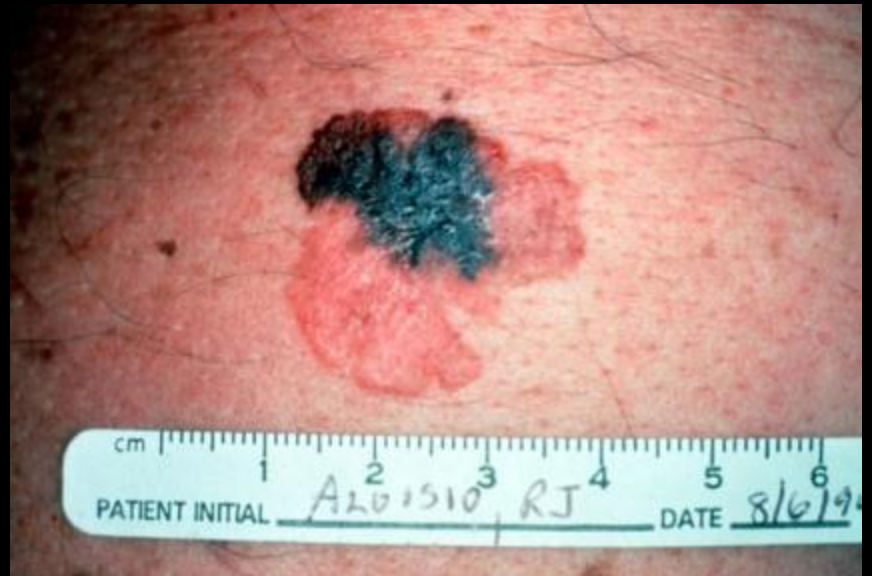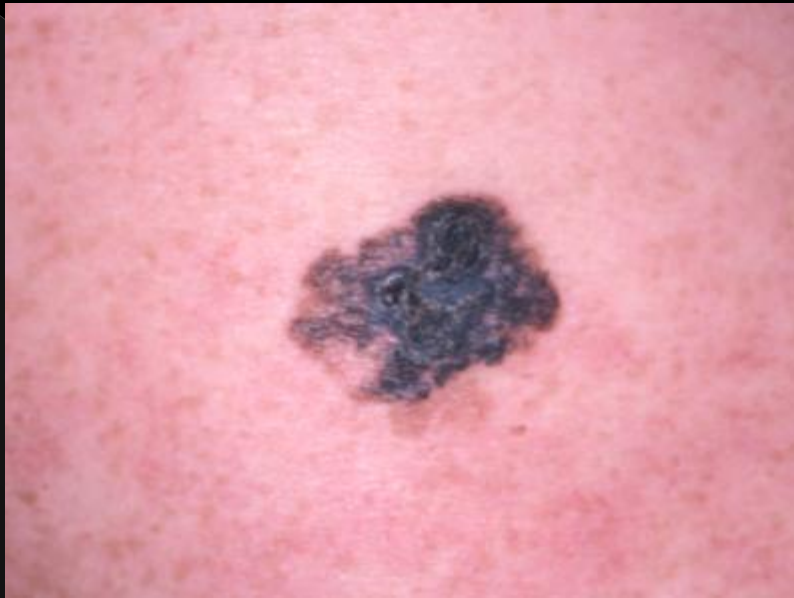- ◉ Basal cell and squamous cell carcinoma should be respected as malignancies
- ◉ Early recognition & definitive treatment provide high cure rate & prevent serious deformity and/or death

Malignant Melanoma

- ◉ Malignant tumor of melanocytes
- ◉ Incidence increasing faster than any other malignancy
- ◉ Current US lifetime incidence approximately 1 in 90
- ◉ Approximately 7500 deaths in US per year
- ◉ Curable if treated definitively at an early stage

Recognition of Malignant Melanoma

- ◉ Asymmetry
- ◉ Border Irregularity
- ◉ Color variegation (Multiple shades of brown, black, often red, grey, even blue and white)
- ◉ Diameter (Greater than 6 mm)
- ◉ Elevation (Grave prognostic sign)



Lentigo Maligna / Melanoma in situ

- Overtaking superficial spreading as most commonly diagnosed form of melanoma
- Long (many years) preinvasive phase as lentigo maligna (melanoma in situ)
- Peak incidence is in 6th to 7th decade
- By far most common on face

Treatment of melanoma in situ

- ◉ Excision with at least 5 mm peripheral margin
- ◉ Frequently surgical margins are found to be positive, necessitating further surgery
- ◉ Mohs surgery with specialized immunostaining can assist in definitive tumor removal.

Immunohistochemical staining of lentigo maligna during Mohs micrographic surgery using MART-1

Larisa C. Kelley, MD,^a and Laurie Starkus, MHT^b *Boston and Worcester, Massachusetts*

Background: Lentigo maligna (LM) often displays extensive subclinical spread. Mohs micrographic surgery (MMS) has been proposed to help delineate the true histologic margin; however, visualizing atypical melanocytes on frozen section is challenging and often requires confirmatory permanent paraffin sections.

Objective: Our aim was to use a monoclonal antibody to rapidly stain frozen sections during MMS to facilitate better visualization of atypical melanocytes.

Methods: Frozen sections of LM during MMS were stained with MART-1 (*melanoma antigen recognized by T cells*) and compared with paraffin-embedded sections.

Results: We found 100% correlation between frozen sections stained with MART-1 and paraffin-embedded sections.

Conclusions: Atypical melanocytes can be better visualized on frozen sections of LM by using MART-1 rather than hematoxylin and eosin. This allows for easier identification during MMS and better chance of complete removal of LM lesions. (*J Am Acad Dermatol* 2002;46:78-84.)

MART-1 Antibody

Immunostaining Melanoma Frozen Sections: The 1-Hour Protocol

GREGORY M. BRICCA, MD,* DAVID G. BRODLAND, MD,[†] AND JOHN A. ZITELLI, MD[†]

**Private Practice, Sacramento, CA, and [†]Private Practice, Pittsburgh, PA*

BACKGROUND. There is significant debate over the use of frozen section processing in Mohs micrographic surgery (MMS) for melanoma. Opponents argue that individual melanocytes are too subtle to view consistently on frozen sections. On the other hand, proponents state that (1) melanocytes are visible on well-prepared frozen sections and (2) MMS using frozen sections for evaluation of melanoma surgical margins achieves comparable recurrence rates when compared with MMS using paraffin-embedded, permanent sections.

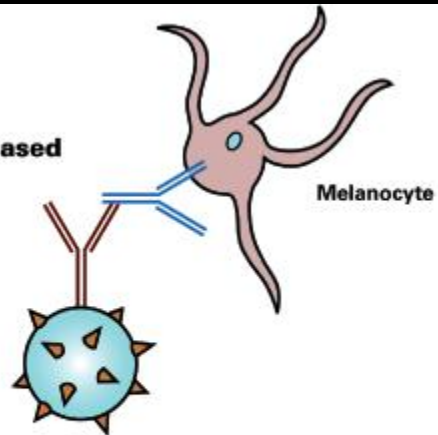
OBJECTIVE. To introduce a new immunohistochemical (IHC) staining protocol that consistently produces melanoma frozen

METHODS. We adapted a polymer-based IHC staining protocol to use with MMS frozen sections for the evaluation of melanoma surgical margins.

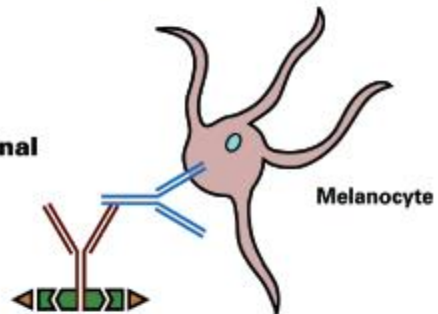
RESULTS. When used with antibody directed against MART-1 for frozen section evaluation of melanoma, the section staining is reproducible and specific for melanocytes.

CONCLUSIONS. In contrast to current IHC protocols that are time consuming (2 to 2.5 hours), we present a new frozen section protocol that takes approximately 1 hour to perform. This technique benefits patients, histotechnicians, and surgeons.

A Polymer-Based



B Conventional



- Primary antibody



- Secondary antibody



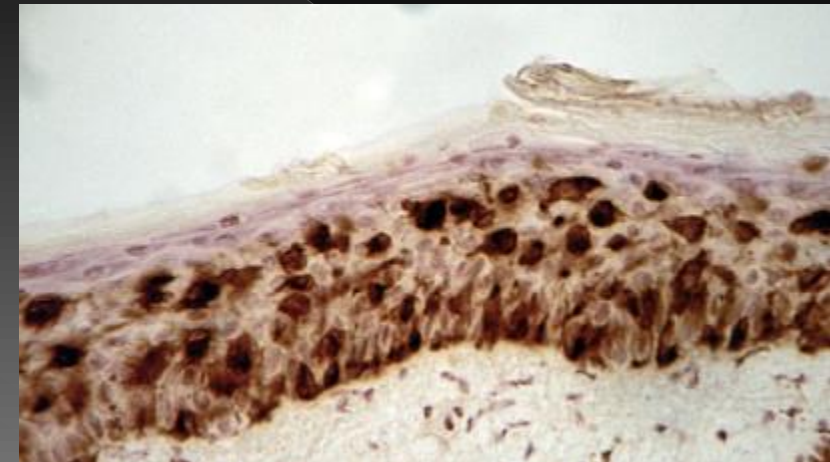
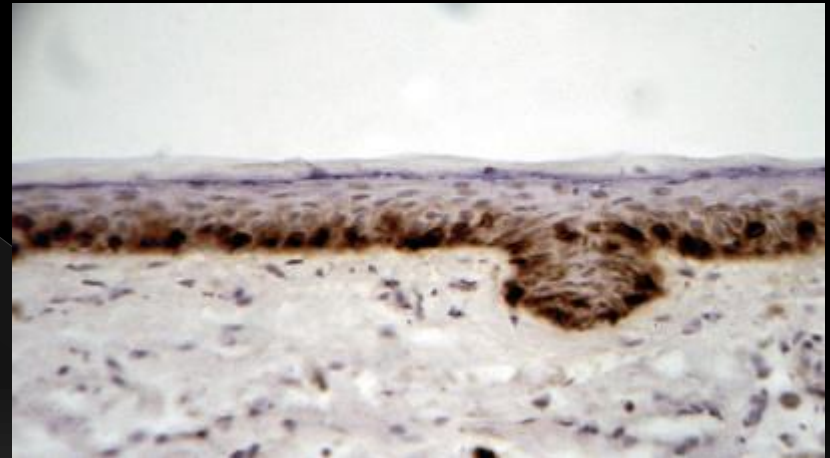
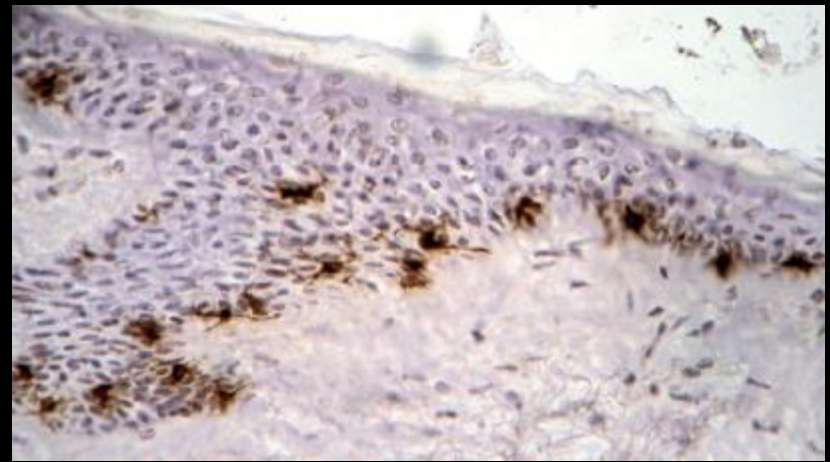
- Chromagen Activators(Determines Intensity of Chromagen)



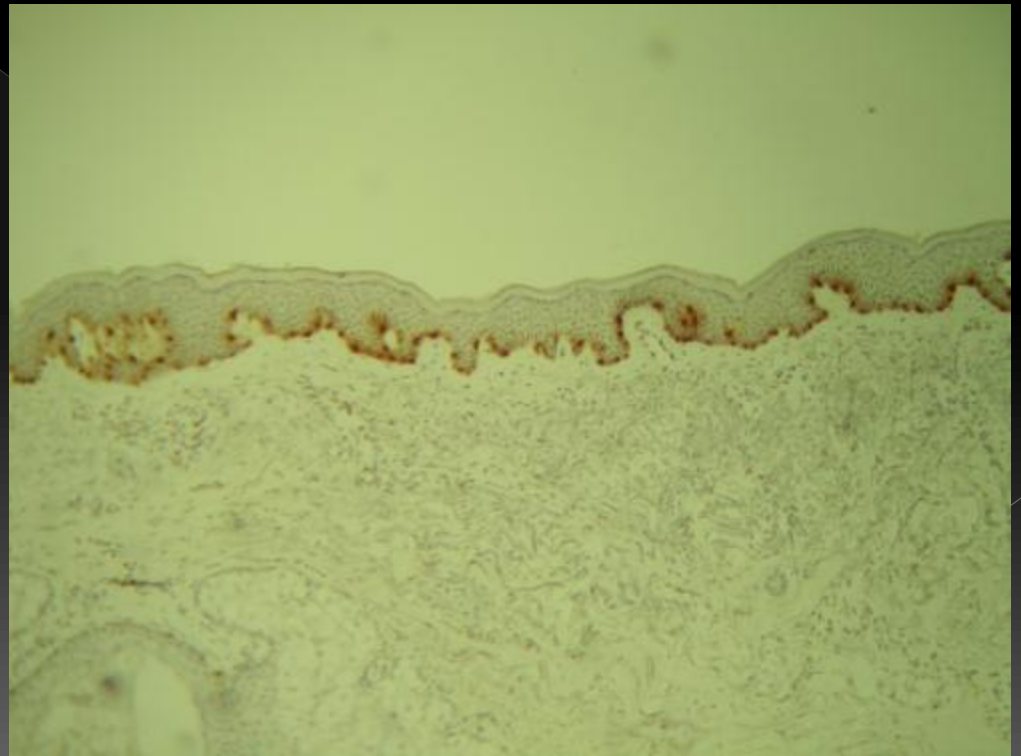
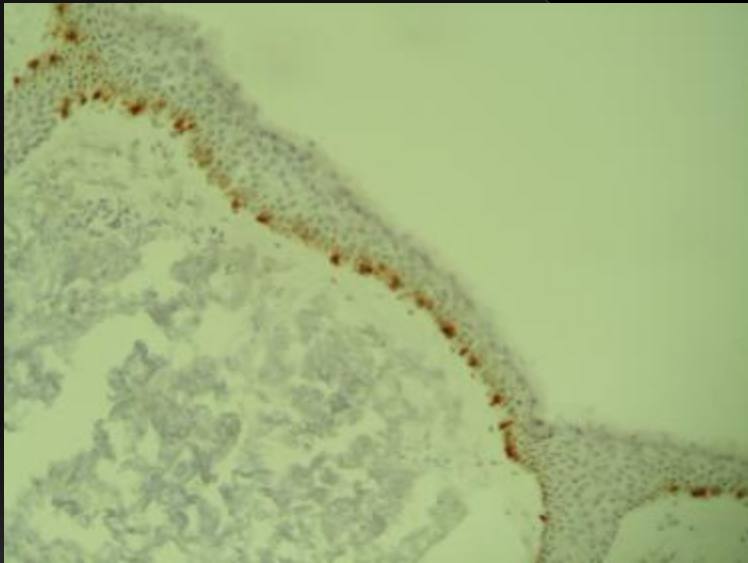
- Link between secondary antibody and chromagen activator



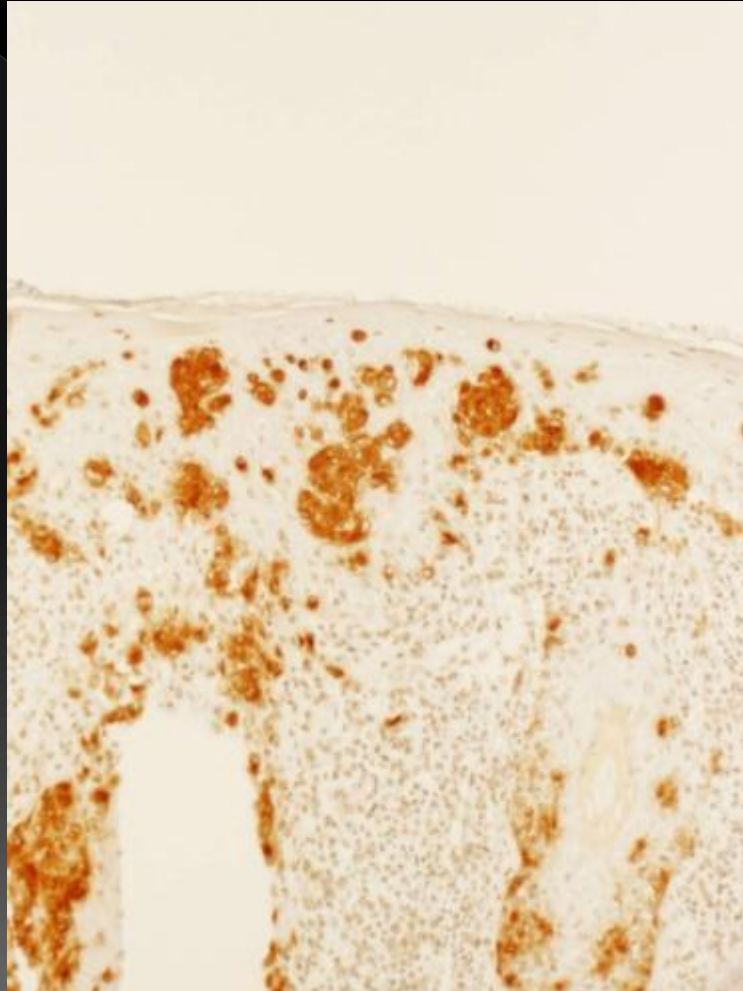
- Polymeric sphere



Normal



Melanoma in situ



MIS

